

Sai Vikram Alampoondi Venkataramanan, MD
University of Nebraska Medical Center
Omaha

saivikramav@gmail.com

(813) 573-8472

Case report (includes case series that include 5 or fewer patients)

Title: A first in literature case report of IGG4 related aortitis and aortic regurgitation managed with Ross procedure.

Description:

Background

Aortitis and aortic regurgitation (AR) are rare manifestations of IgG-4-related disease (IgG-4RD). We report only the second case of severe aortic regurgitation (AR) and aortitis caused by IgG-4RD and the first to be managed with the Ross procedure.

Case

A 37-year-old healthy female was found to have a 5.1cmX2.8 cm aneurysm of the sinus of Valsalva and severe AR on TTE done for evaluation of a diastolic murmur. A CT angiogram (Pic 1,2&3) and TEE (Pic 4,5&6) confirmed the aneurysm and showed an additional saccular aneurysm of the descending thoracic aorta. Infectious, rheumatologic workup for aortitis (including a normal serum Ig-G4 level) and genetic evaluation for heritable aortopathy were negative.

Decision Making

As she desired future pregnancy, she underwent Ross procedure for the replacement of the aortic root along with a 26 mm pulmonary homograft placement, aortic annular stabilization, and replacement of proximal ascending aorta with a 28 mm tube graft. The tissue from the sinus of Valsalva was friable. Histopathology showed plasma lymphocytic infiltration and 53 Ig-G4 positive cells per high power field in the adventitia. The patient was started on prednisone four weeks after surgery to reduce the risk of delayed wound healing with a slow taper. A repeat echo at one year showed normal function of the neoaortic valve. A repeat CTA showed a stable aneurysm in the descending aorta.

Conclusion

IgG-4RD should be considered in the differential diagnosis of aortopathy in a young person. Ross procedure can serve as an effective therapeutic option for patients with severe AR from aortitis who wish to avoid a mechanical valve. Further studies are needed to compare the efficacy of different surgical options for IgG-RD aortic valve disease. "

A first in literature case report of IGG4 related aortitis and aortic regurgitation managed with Ross procedure.

Background

Aortitis and aortic regurgitation (AR) are rare manifestations of IgG-4 related-disease (IgG-4RD). We report only the second case of severe aortic regurgitation (AR) and aortitis caused by IgG-4RD and the first to be managed with the Ross procedure.

Case

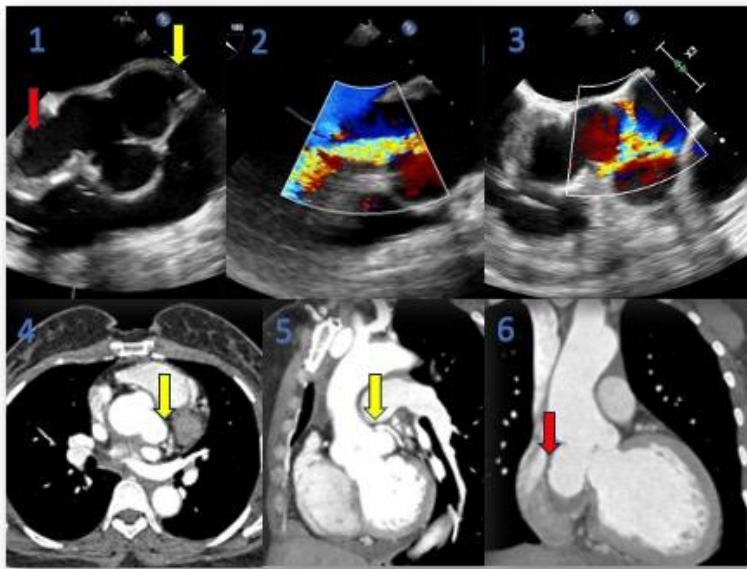
A 37-year-old healthy female was found to have a 5.1cmX2.8 cm aneurysm of the sinus of Valsalva and severe AR on TTE done for evaluation of a diastolic murmur. A CT angiogram (Pic 1,2&3) and TEE (Pic 4,5&6) confirmed the aneurysm and showed an additional saccular aneurysm of the descending thoracic aorta. Infectious, rheumatologic work up for aortitis (including a normal serum Ig-G4 level) and genetic evaluation for heritable aortopathy were negative.

Decision Making

As she desired future pregnancy, she underwent Ross procedure for replacement of the aortic root along with a 26 mm pulmonary homograft placement, aortic annular stabilization and replacement of proximal ascending aorta with 28 mm tube graft. The tissue from the sinus of Valsalva was friable. Histopathology showed plasma lymphocytic infiltration and 53 Ig-G4 positive cells per high power field in the adventitia. The patient was started on prednisone four weeks after surgery to reduce the risk of delayed wound healing with a slow taper. A repeat echo at one year showed normal function of the neoaortic valve. A repeat CTA showed a stable aneurysm in the descending aorta.

Conclusion

IgG-4RD should be considered in the differential diagnosis of aortopathy in a young person. Ross procedure can serve as an effective therapeutic option for patients with severe AR from aortitis who wish to avoid a mechanical valve. Further studies are needed to compare the efficacy of different surgical options for IgG-RD aortic valve disease.



Pictures 1, 2 & 3 TEE showing aneurysm of the left coronary (yellow arrow) and non coronary sinuses (red arrow) of Valsalva and severe aortic regurgitation.

Pictures 4 & 5 CT angiogram in axial plane and sagittal plane showing aneurysm of the left coronary sinus of Valsalva (yellow arrow)

Picture 6 CT angiogram in coronary plane showing aneurysm of the non coronary sinus of Valsalva (red arrow)